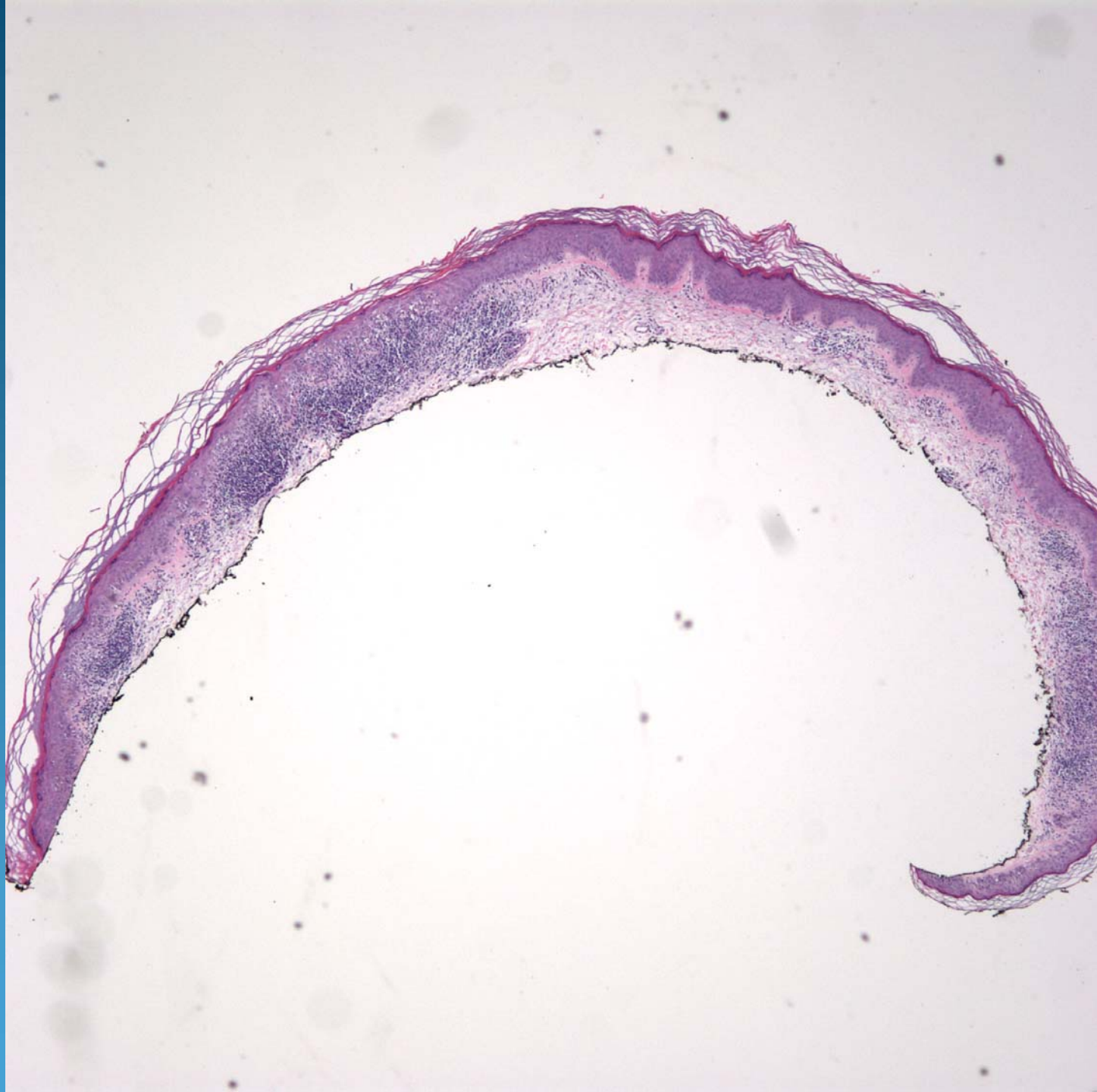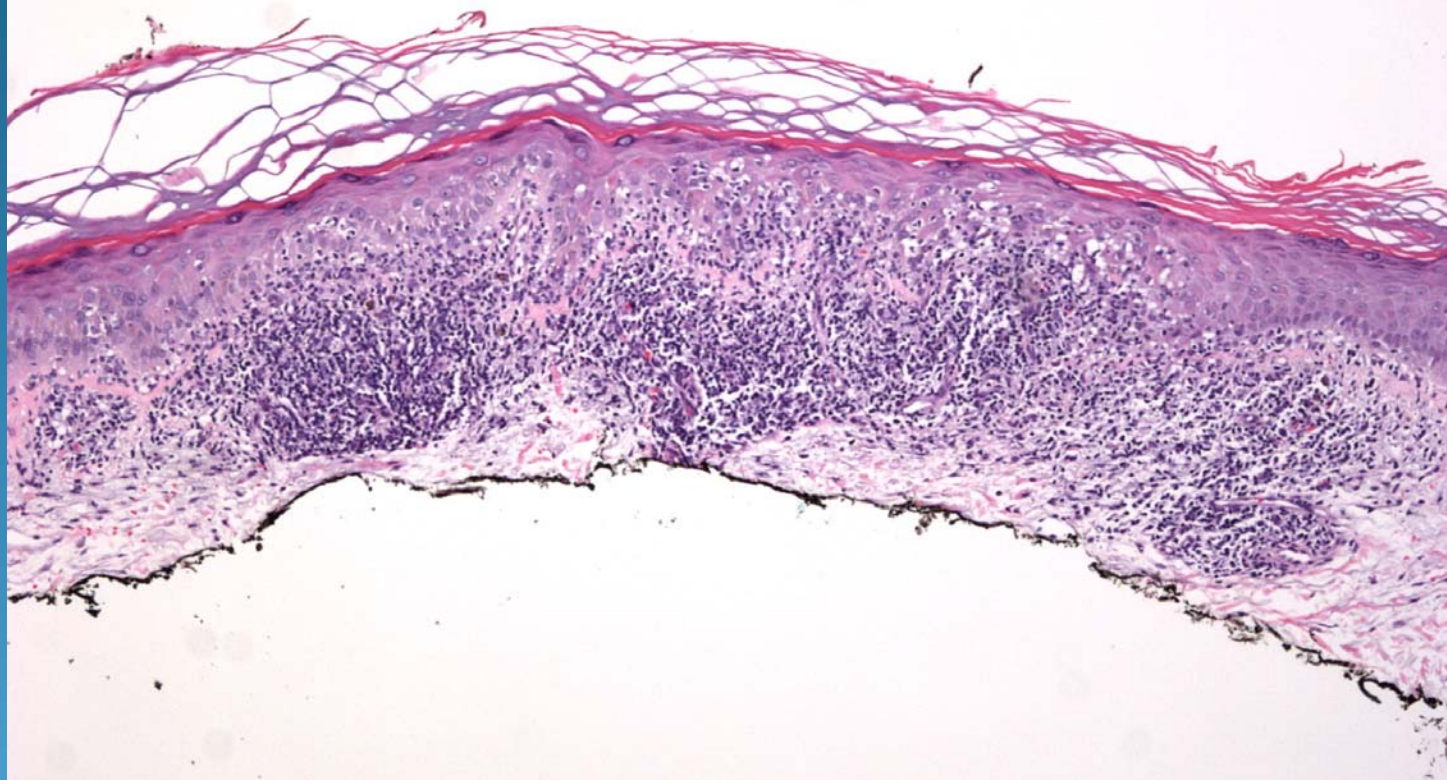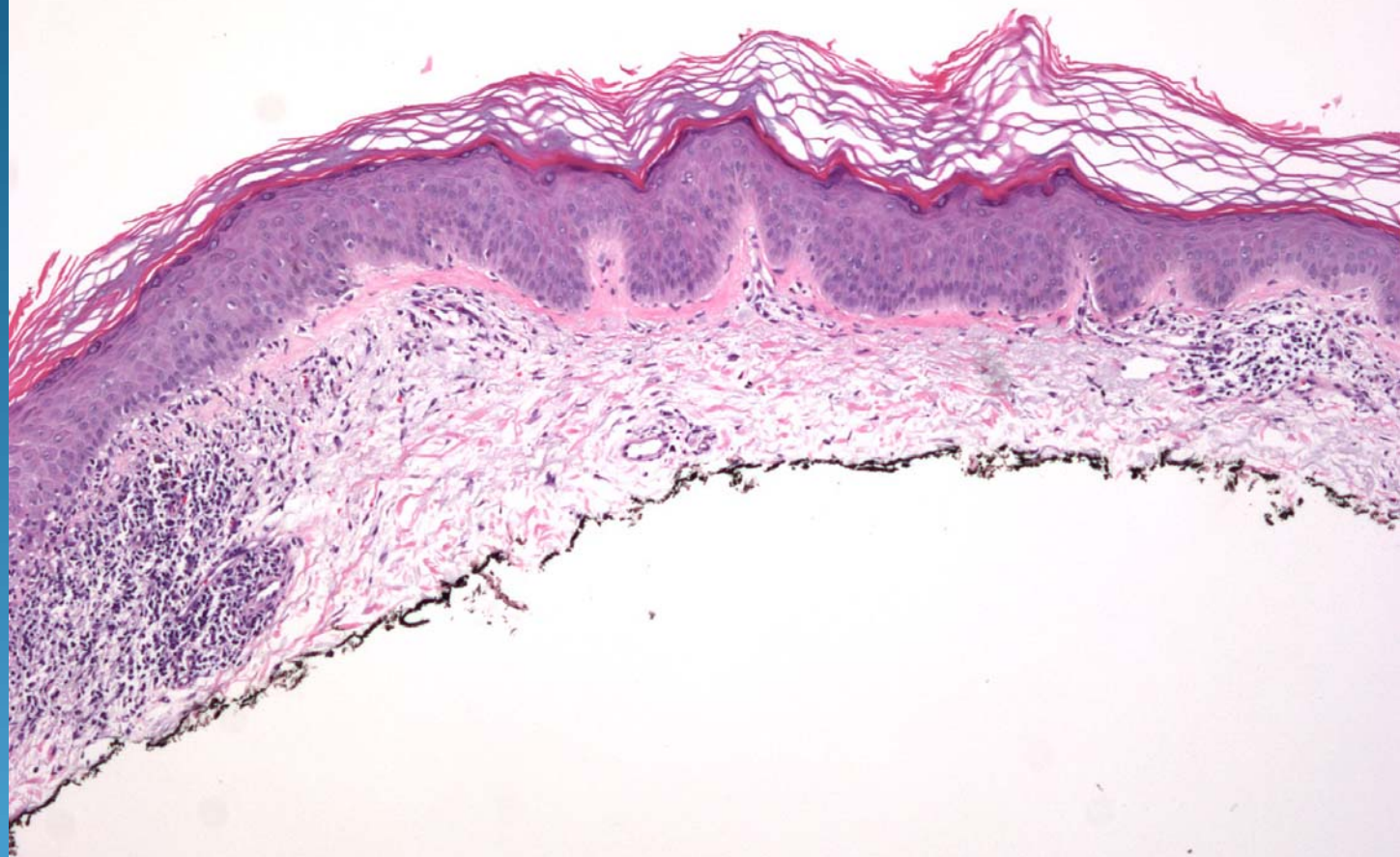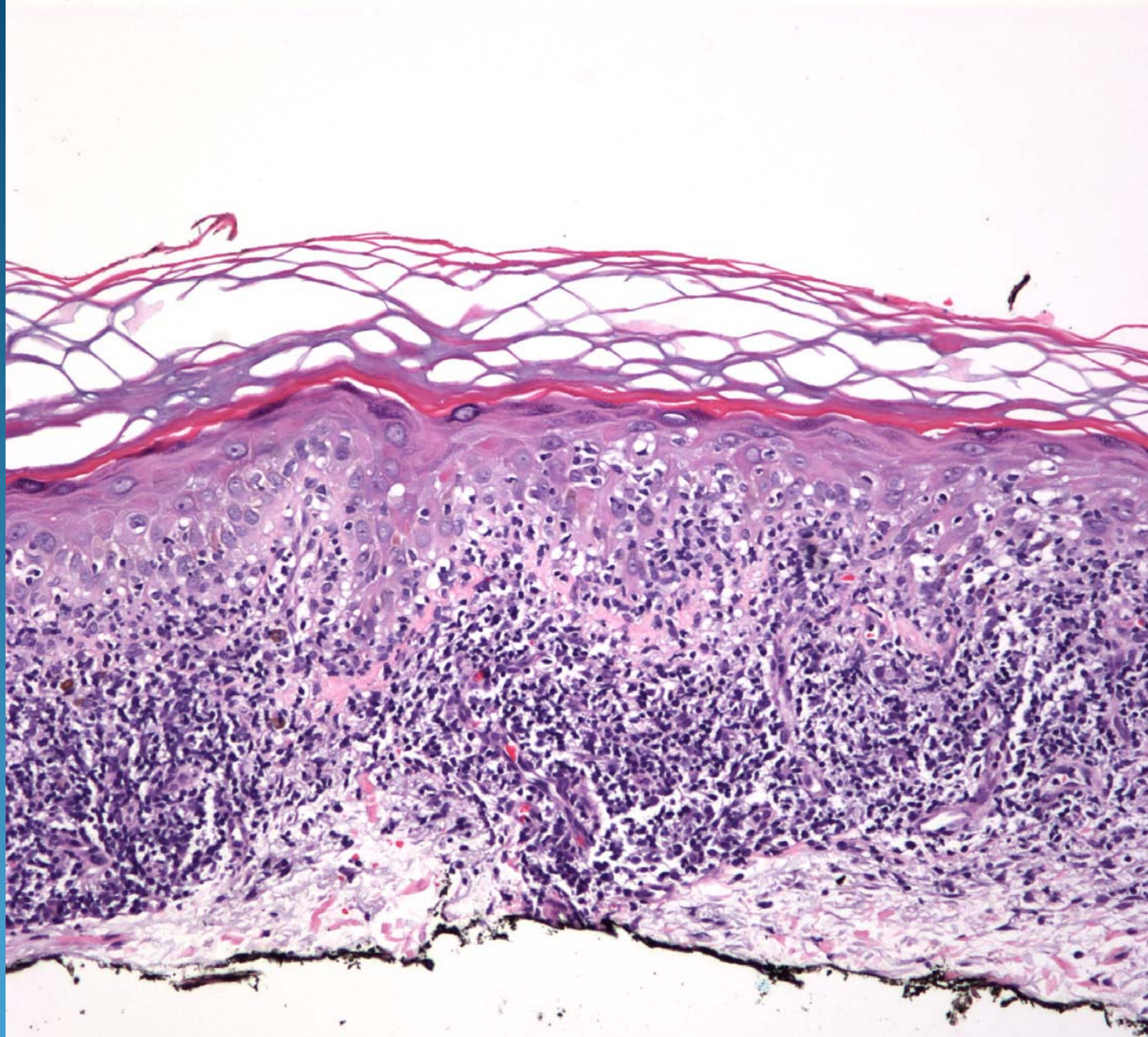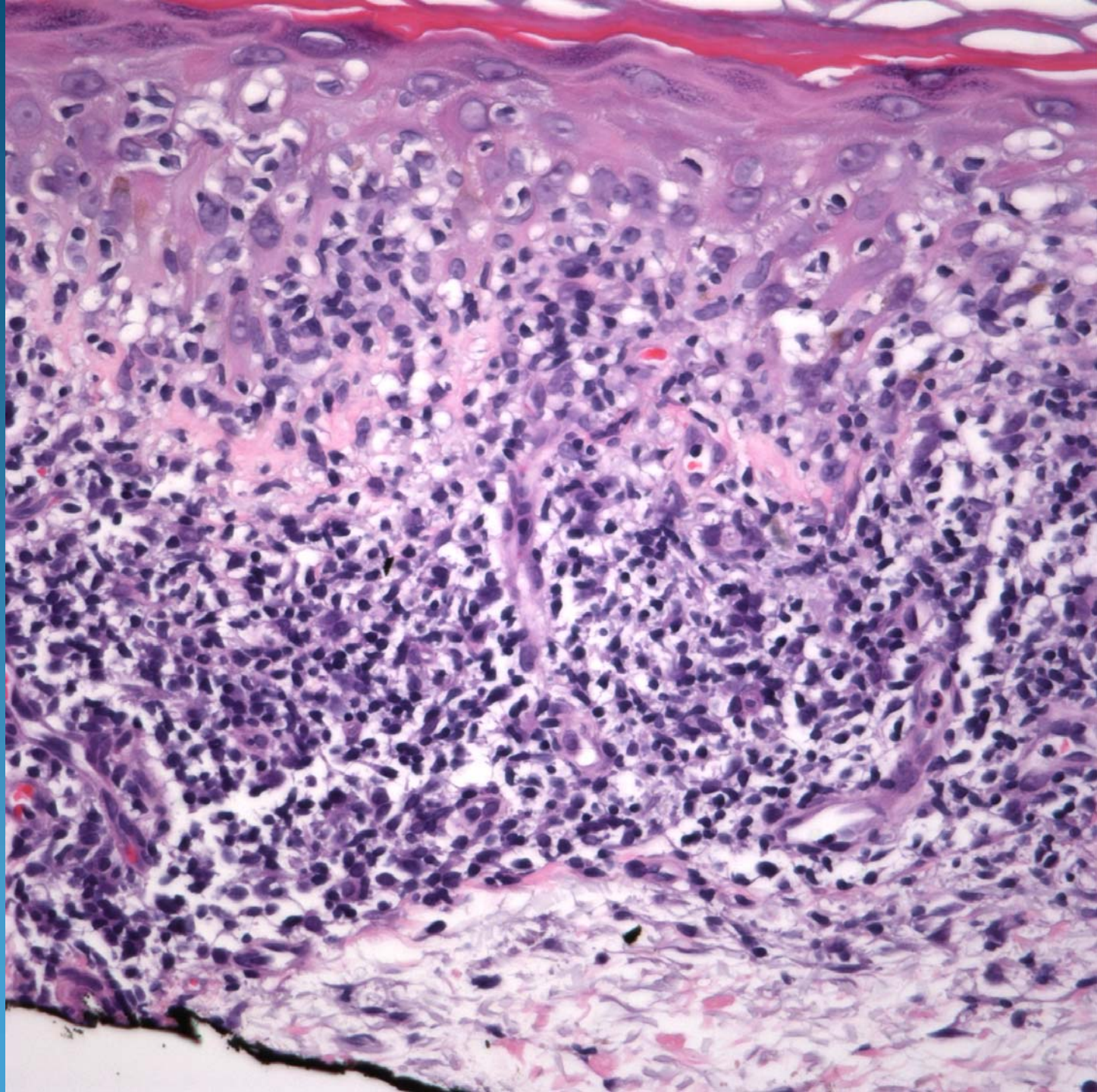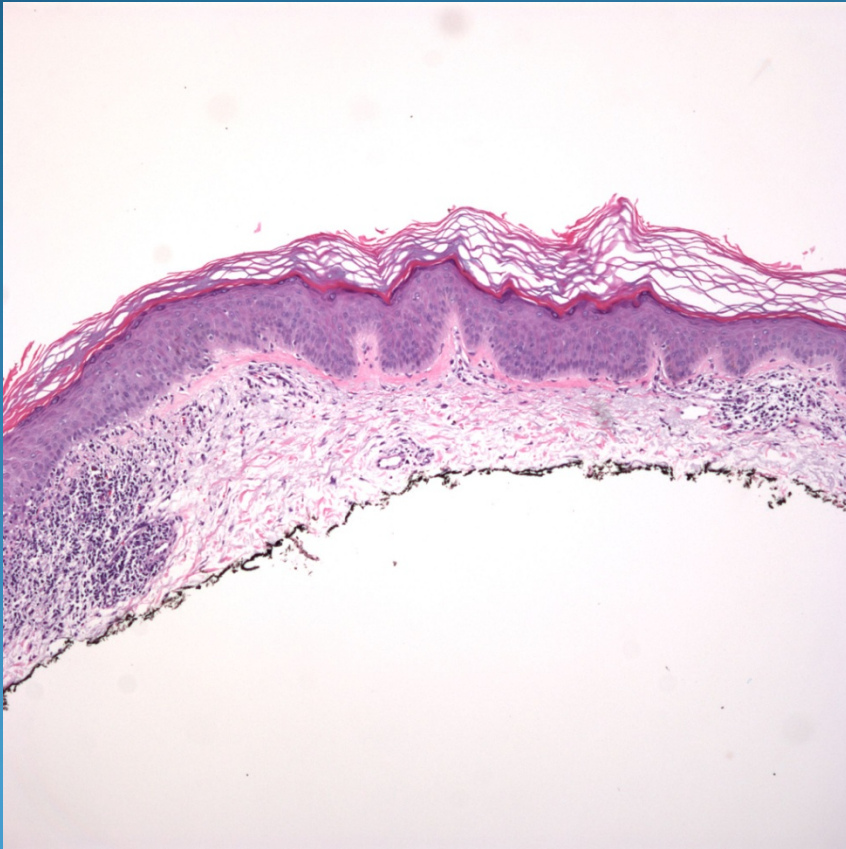


Lichen Planus-like Keratosis

Pearls



- Low power view of lichenoid infiltrate adjacent to lentigo or seborrheic keratosis
- Patchy irregular inflammation, often with parakeratosis
- DDX with clinical history-solitary vs. disseminated